Biomedicine & Pharmacotherapy 165 (2023) 115176

Contents lists available at ScienceDirect

Biomedicine & Pharmacotherapy

journal homepage: www.elsevier.com/locate/biopha

Protective effect of vaginal resveratrol administration on joint tissues in ovariectomized rats: Targeting mTOR and caspase 3

Ganna Zaychenko [a,*], Igor Belenichev [b], Valeriia Hnatiuk [a], Andrii Doroshenko [b], Oksana Sinitsyna [c], Oksana Sulaieva [d], Tetyana Falalyeyeva [d,e], Nazarii Kobyliak [d,f,**]

[a] Pharmacology Department, Bogomolets National Medical University, Kyiv, Ukraine
[b] Department of Pharmacology and Medical Formulation with Course of Normal Physiology Zaporizhzhya State Medical University, Zaporizhzhya 69000, Ukraine
[c] Department of Clinical Pharmacology, Institute for Advanced Training of Pharmacy Specialists, National University of Pharmacy, Kharkiv 61002, Ukraine
[d] Medical Laboratory CSD, Kyiv 02000, Ukraine
[e] Taras Shevchenko National University of Kyiv, Kyiv 01601, Ukraine
[f] Endocrinology Department, Bogomolets National Medical University, Kyiv 01601, Ukraine

ARTICLE INFO

Keywords:
Resveratrol
Polyphenols
Hyaluronic acid
Menopause
Joint tissues
Osteoporosis
Vaginal gel

ABSTRACT

Introduction: Estrogens play a considerable role in maintaining bone and articular cartilage homeostasis. Menopause provokes joint disorders due to metabolic syndrome and altered signaling pathways. Phytoestrogen resveratrol was demonstrated to provide chondroprotective and osteoprotective effects. However, the mechanisms of such action of Resveratrol are still being explored.

Aim: The study aims to determine the effect of Resveratrol on the joints and its therapeutic mechanism in ovariectomized rats.

Material and methods: The study was carried out on Wistar female rats that were divided into three groups, including control animals; ovariectomized rats (OVX); and the OVX group treated with an intravaginal gel containing Resveratrol (0.5 % 0.1 mL, daily 28 days). Knee joint tissues (articular cartilage, subchondral plate, subchondral bone) were assessed by histomorphometry. The expression of mTOR, PTEN, Caspase 3 and BCL-2 in articular cartilage and subchondral bone were evaluated immunohistochemically.

Results: Resveratrol treatment of OVX rats prevented weight gain by 17 % ($P < 0.001$), demonstrating the systemic effect on metabolic pathways. Although there were no statistically significant differences in the thickness of articular cartilage between groups, OVX rats possessed degenerative changes in chondrocytes, associated with the enhanced expression of mTOR ($P < 0.001$) and Casp-3 ($P = 0.005$). Resveratrol decreased mTOR ($P = 0.007$) and Casp-3 ($P = 0.011$) expression in chondrocytes, reducing degenerative changes. At the same time, resveratrol attenuated the deterioration of trabecular bone in OVX rats ($P = 0.002$). This effect was through the up-regulation of BCL-2 ($P = 0.018$) and down-regulation of Casp-3 expression ($P < 0.001$).

Conclusions: Intravaginal administration of resveratrol provided systemic effects and ameliorated joint tissue structure and signaling in OVX rats through stimulation of BCL-2 and reduced Casp-3 expression.

1. Introduction

One of the most critical problems of modern medicine is related to the aging of the population and the growth of the age group of people older than 60 years. The amount of elderly people worldwide is increasing every year. According to forecasts, their number may double in the next 35 years [1]. Therefore, the share of women of the older age group in the climacteric period is also progressively increasing yearly. Menopause is diagnosed after a woman has gone one year without a menstrual period (usually 45–55 years of age) [2,3]. During menopause, the functions of organs and systems fade due to decreased synthesis and secretion of sex steroid hormones – estrogens [4,5].

Clinical manifestations that occur due to a decrease in the synthesis of estrogens are diverse. They can be divided by time: the early ones include vasomotor, psychoemotional to medium-genitourinary disorders, sexual dysfunction, atrophic changes in the skin, mucous

* Corresponding author.
** Correspondence to: Endocrinology Department, Bogomolets National Medical University, Kyiv, Ukraine.
E-mail addresses: ganna.zaychenko@ukr.net (G. Zaychenko), nazariikobyliak@gmail.com (N. Kobyliak).

https://doi.org/10.1016/j.biopha.2023.115176
Received 25 May 2023; Received in revised form 4 July 2023; Accepted 12 July 2023
Available online 20 July 2023
0753-3322/© 2023 The Authors. Published by Elsevier Masson SAS. This is an open access article under the CC BY-NC-ND license (http://creativecommons.org/licenses/by-nc-nd/4.0/).

membranes of the vagina, nails, and hair; late clinical manifestations, which are accompanied by dramatic consequences and include menopausal metabolic syndrome, which is caused by atherosclerosis, arterial hypertension, neurological symptoms, and osteoporosis [6–10].

Diseases of the musculoskeletal system evolution are typically slow and can take years to develop, with resultant joint pain and stiffness, mobility limitations, and compromised quality of life. Estrogens play a considerable role in maintaining bone and articular cartilage homeostasis [11]. Menopause provokes joint disorders due to altered signaling pathways. Unfortunately, no curative treatments for joint diseases in menopause are available today, and most conventional therapies (medications, physiotherapy, mechanical devices) provide relatively short-term, unsustained relief of the symptoms [12].

Phytoestrogens are widely used to treat menopausal symptoms as hormone replacement therapy [13]. Resveratrol (R) is structurally similar to natural and synthetic estrogens and was ranked as a phytoestrogen. Previous studies demonstrated that R binds directly to nuclear estrogen receptor (ER), modulating its genomic activity, and can interact with membranous ER, contributing to non-genomic estrogen--like effects [14]. The dietary polyphenol possesses antioxidant, cytoprotective and anti-inflammatory properties [15–18]. Phytoestrogen R was demonstrated to provide chondroprotective and osteoprotective effects. It can bind to estrogen receptors on bone and cartilage cells. As a result, there is an increase in the expression of genes that have osteoprotective and chondroprotective impacts [19]. Several experimental studies have shown the protective effects of oral resveratrol intake on bone tissue in different animal models of osteoporosis [20–23].

One of the possible protective mechanisms of R action is regulating cell death by modulating the expression of molecules responsible for the execution of apoptosis (Caspase-3) and anti-apoptotic agent (BCL-2). Recently it was demonstrated that the expression of Casp-3 (cysteine proteinase playing a central role in the execution phase of cell apoptosis) and BCL-2 (B cell lymphoma/leukemia-2) are related to ovarian hormone levels [24]. Ovariectomy, causing hypoestrogenemia can disrupt cell survival, inducing cell apoptosis. As R acts as an ER agonist, it is supposed that R-treatment can modulate signaling pathways in the target cells under the OVX setting.

On the other hand, there are mutual and complex relationships between estrogens and mTOR-mediated signaling. It was shown previously that estrogen binding to ERα triggers the expression of the target genes through the genomic pathway. Still at the same time ERα can modulate the cytoplasmic signaling pathways, including PI3K/AKT/mTOR [25]. mTOR affects various aspects of cells' functioning, growth, metabolism and death. In another study it was established that R enables a significant reduction in the expression of inflammatory cytokines in cartilage cells, increases the activation of the PI3K/AKT signaling pathway and regulates the expression of BCL-2 and Bax, which results in the alleviation of the inflammatory response in chondrocytes and leads to a reduction in chondrocyte apoptosis [26]. So, the assessment of mTOR and its antagonist PTEN expression in joint tissues can provide insights into the understanding of OVX-related arthropathy and mechanisms of protective R action.

The study aims to decipher the mechanisms of R effects when administered as vaginal gel on joint tissues in ovariectomized rats.

2. Material and methods

2.1. Ethics statement

This study was carried out in strict accordance with the recommendations in the Guide for the Care and Use of Laboratory Animals of the National Institutes of Health and the general ethical principles of animal experiments (Strasbourg, 1985), approved by the First National Congress on Bioethics Ukraine (September 2001). Guide for the Care and Use of Laboratory Animals and approved by the bioethics commission of Bogomolets National Medical University (Protocol number: 4/2021).

Table 1
Experimental groups and experimental conditions [24].

Experimental group	Experimental conditions	Dose according to the drug form
Control rats (n = 7)	Intact animals were intravaginally administered with saline in the same time as intervention group	0.1 mL / day
OVX (n = 7)	Females after bilateral ovariectomy were intravaginally administered with saline	0.1 mL / day
R-HA (n = 7)	Ovariectomized females were intravaginally administered 0.5 % gel with R and HA	0.1 mL / day

2.2. Study design

The study was carried out on 21 Wistar female rats aged 6–8 months. The animals were raised in the vivarium nursery of the Bogomolets National Medical University. Rats were kept in a clean, ventilated room with a controlled temperature (20–25 °C), relative humidity (50–55 %), and a 12-hour light-dark cycle [24]. They were fed standard laboratory rodent chow with water available ad libitum. The rats were acclimatized for one week before the start of the experiment. Bilateral ovariectomy of females was performed in aseptic conditions under thiopental anesthesia (70 mg/kg, intraperitoneal) as previously described [27]. After castration, the females were kept in an accessible model for five weeks. This time was necessary for developing hypoestrogenemia. On the 35th day of the experiment, OVX-rats were administered, with the help of an insulin syringe with an atraumatic tip once a day for 28 days, 0.1 mL of test samples of R-HA (R-HA group) or saline (OVX-group and control group) (Table 1).

2.3. Drugs

Test samples of vaginal gel with R-HA were developed under the guidance of Professor Ruban O. A. at the Department of Industrial Technology of the National University of Pharmacy (Kharkiv). The gel contains R, which is a polyphenol, a phytoestrogen that does not require prior metabolism to detect pharmacological action (unlike soy isoflavones), HA and excipients, including lactic acid (LA) [24]. R substance containing 50 % trans-resveratrol of plant origin, was obtained from *Polygonum Cuspidatum*. According to dose escalation studies previously reported [24], test samples of vaginal gels containing different R dosage (0.5 %, 1 %, 2 %, 3 %), HA (0.5 %) and auxiliary substances were investigated. The proposed gels were effective under conditions of intravaginal 28-day administration to OVX female rats, as they decrease body weight gain, normalized the tail temperature, contributed to the restoration of the normal vaginal microflora and the acidic environment of vaginal secretions, and prevented the development of atrophic changes in the vaginal mucosa. Based on the results of an integral assessment of the therapeutic effect of vaginal gels, it was established that the optimal R content in the dosage form is 0.5 % [24]. In their composition, additionally to R-HA, vaginal gel contains auxiliary substances: sodium alginate, aristoflex AVC, propylene glycol, preservative, lactic acid and purified water.

2.4. Histological evaluation of joint tissues

The joint tissues were fixed in 10 % neutral buffered formalin for 72 h. After that, the decalcification was performed using rapid decalcificant (Kaltek, Italy). Then tissues were processed and embedded into paraffin. Paraffin-embedded blocks were cut 4 μm thickness. For routine histological evaluation, sections were stained with hematoxylin and eosin (HE).

The histological assessment included an evaluation of the articular cartilage and subchondral bone. The following features were evaluated in articular cartilage: surface discontinuity, cartilage thickness,

Table 2
Biomarkers characteristics.

Biomarkers	Rationale	Antibody characteristics
BCL-2	BCL-2 is a mitochondrial membrane protein that blocks the apoptotic death of various cells by controlling mitochondrial membrane permeability	DAKO, clone 124, catalog number IR614
Caspase 3	Caspase-3 is a cysteine proteinase playing a central role in the execution phase of cell apoptosis. It is considered as one of the biomarkers of pro-apoptotic signaling	Diagnostic Biosystems, clone D3R6Y, catalog number RP 096–05
mTOR	mTOR, also known as the Mechanistic Target Of Rapamycin Kinase, belongs to a family of phosphatidylinositol kinase-related kinases (PI3K), mediating cellular responses to stresses, including DNA damage or nutrients deprivation. It is also involved in regulating cell growth, survival and proliferation. Ageing and menopause are associated with the upregulation of mTOR in various cell lines[40].	Termo Fisher Scientific, clone EPR426(2), catalog number PA1–518
PTEN	PTEN (Phosphatase and Tensin Homolog) is a tumor suppressor and negatively regulates mTOR/AKT/PIK3 signaling.	BiocareMedical, clone 6H2.1, catalog number CM278A,

Table 3
Scoring system for assessing the articular cartilage and trabecular bone immunostaining.

Grade	Number of immunopositive cells (chondrocytes and osteoblasts)
0	no cells are stained
1	<25 % of cells are stained
2	25–50 % of cells are stained
3	50–75 % of cells are stained
4	>75 % of cells are stained

chondrocytes` orientation, proliferation, hypertrophy, grouping, and death. In addition, we assessed the tidemark regularity and subchondral bone changes. The subchondral trabecular bone was evaluated with respect to the mean thickness of the trabeculae (TT; μm) and the width of trabecular spaces (TS, μm) as the mean distance between trabeculae [28].

2.5. Immunohistochemistry (IHC)

To assess the possible mechanisms of resveratrol action on joint tissues, the expression of the following biomarkers was assessed: mTOR1, PTEN, Caspase 3 and BCL-2 using immunohistochemical staining kits (Table 2). For IHC, serial Section 4 μm in thickness were used. Tissues were deparaffinized and hydrated. Endogenous peroxidase activity was blocked using 3 % methanol in hydrogen peroxide. Next, antigen retrieval in a water bath at 98 ∘C was performed using Tris EDTA or citrate buffer (pH6), followed by primary antibodies incubation. After washing, labeled polymer secondary antibodies (Envision Detection System, Dako, CA, USA) were added to the slides. Peroxidase activity was detected using diaminobenzidine (DAB)—tetrahydrochloride liquid plus Chromogen System (Dako) substrate. The reaction was stopped with distilled water. After that, sections were counterstained with hematoxylin and mounted in Richard–Allan Scientific Mounting Medium (ThermoFisher, Waltham, MA, USA).

Assessing the IHC results, we considered the number of immunopositive cells [29]. The semi-quantitative scoring system was used to assess the immunostaining of the articular cartilage and bone cells (Table 3).

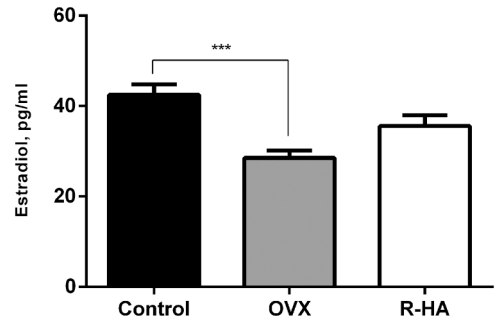

Fig. 1. Serum estradiol levels in control, ovariectomized rats and after 4 weeks of resveratrol and hyaluronic acid gel. Data are presented as the M±SEM. One-way ANOVA with post hoc Tukey's test for multiple comparisons were performed for data analysis. * **P = 0.001.

2.6. Estradiol measurement

The content of estradiol in the serum of female rats was performed by enzyme-linked immunosorbent assay on Stat Fax 303 plus (Awareness Technology, Palm City, FL, USA) using standard sets of reagents "Estradiol ELISA" (LLC "HEMA", Kharkiv, Ukraine) according to instructions.

2.7. Statistical analysis

Statistical analysis was performed by using SPSS-21 and GraphPad Prism 7 software. All normally distributed variables were expressed as mean ± standard error (M±SEM). Median values, 25th and 75th percentiles were used to present non-normally distributed variables. Data distribution was analyzed using the Kolmogorov–Smirnov normality test. Normally distributed continuous variables were analyzed with Analysis of Variance (one-way ANOVA) and if the results were significant, a post-hoc Turkey's test was performed. Non-normally distributed continuous variables were assessed with non-parametric Kruskall-Wallis test. P value of < 0.05 was considered statistically significant.

3. Results

3.1. Systemic effects of R-treatment

Ovariectomy resulted in weight gain in the 5th week after surgery. Weight of ovariectomized rats is 23.2 % higher as compared to initial figures (260.17 ± 1.92 vs 211.33 ± 1.15 g, $P < 0.05$) and intact rats (260.17 ± 1.92 vs 217.83 ± 2.51 g, $P < 0.05$).

The administration of R-HA intravaginally for 4 weeks led to the slowing of the rate of weight gain. As a result, at 28-day the weight of the treated rats was 17 % ($P < 0.001$) lower as compared to OVX rats ($P < 0.05$). The total body weight gain was not more than 6.05 % as compared to the intact rats.

Naturally, serum estradiol dropped significantly after the 4th week of OVX as compared to control ($P = 0.001$). An assessment of estradiol levels in the serum of R-treated rats revealed the trend of estradiol elevation (35.6 ± 2.32 vs. 28.54 ± 1.6 pg/mL, $P = 0.072$). However, its level did not reach the values of the intact rats. So, R-treatment provided a limited effect on systemic levels of estradiol in OVX rats (Fig. 1).

Thus, intravaginal administration of R provided a systemic effect that resulted in reduced weight gain and elevation of estradiol levels in ovariectomized rats.

3.2. Joint tissue changes after OVX and effects of R-treatment

In intact rats, the articular cartilage demonstrated a smooth surface and three distinct layers, including superficial, intermediate, and deep zones reflecting chondrocytes heterogeneity because of differentiation.

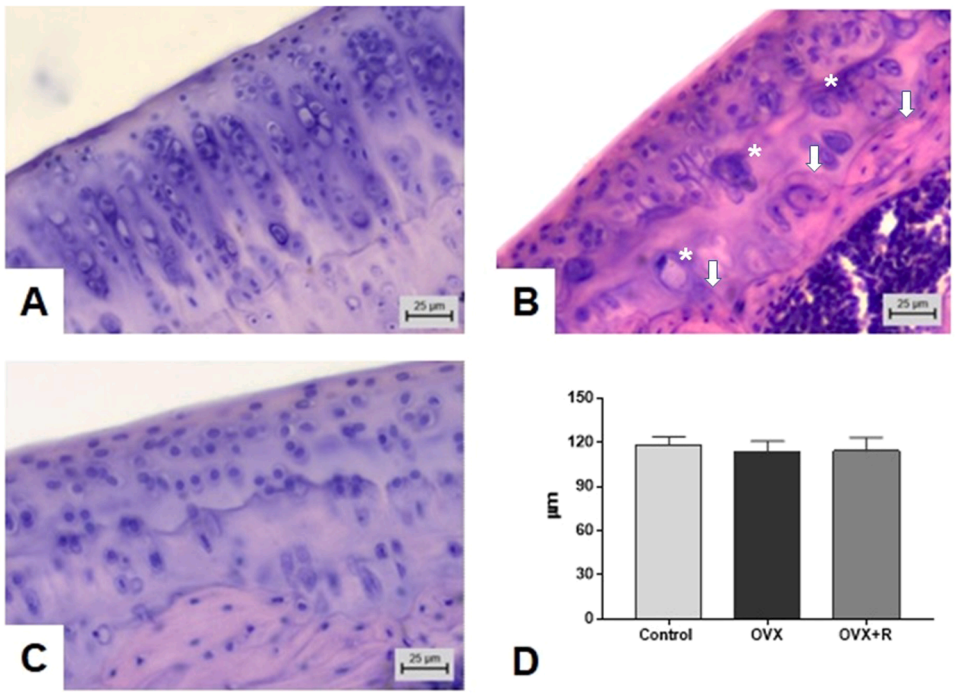

Fig. 2. Structural changes in rats joint tissues after ovariectomy (OVX) and resveratrol with hyaluronic acid gel (R-HA) treatment. Comparing to control group (A), OVX-induced structural changes in articular cartilage (B), demonstrating mid-zone chondrocytes disarrangement and dystrophy (asterisk) associated with the irregular tidemark (arrows) and remarkable thinning of the subchondral plate. R-treatment attenuated cartilage dismorphogenesis with no effect on articular cartilage thickness (D). A – control group, B – OVX rats, C – OVX rats after R-HA treatment. Hematoxylin and eosin staining (A-C). In Fig. D data presented as the M±SEM. One-way ANOVA was used for comparison. Changes were not statistically significant.

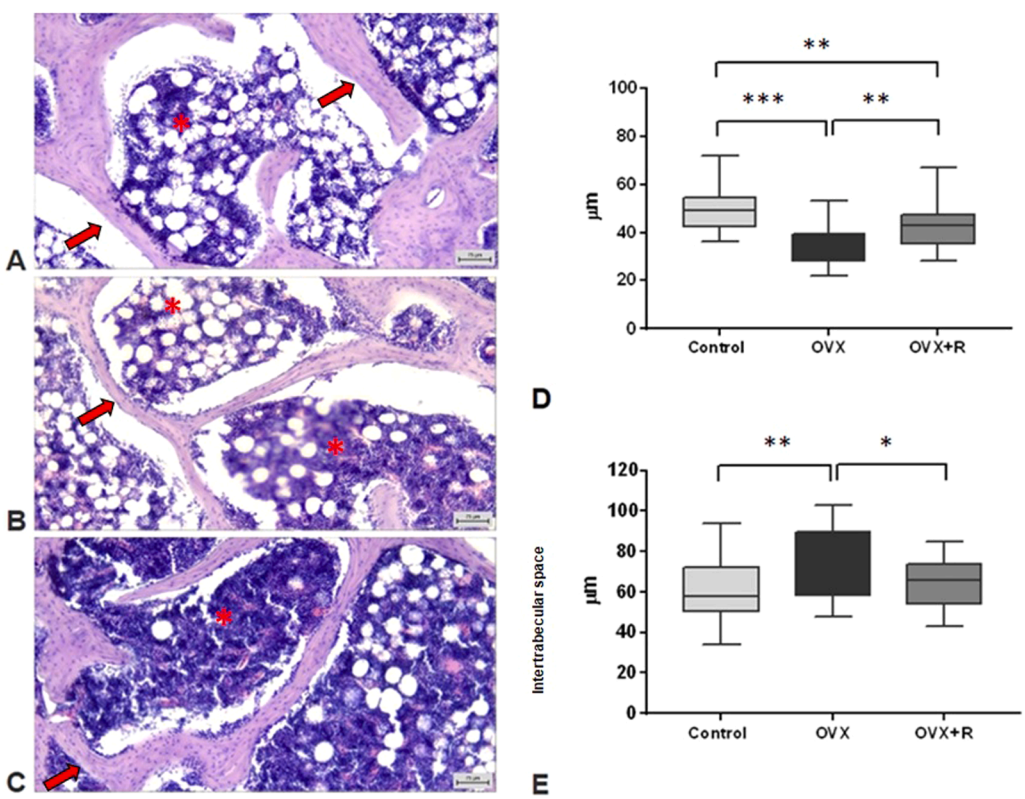

Fig. 3. Effect of resveratrol with hyaluronic acid gel (R-HA) on trabecular bone in ovariectomized (OVX) rats. In contrast to control group (A), estrogen depletion (B) led to loss of trabecular bone that was prevented by R-HA administration in OVX-rats (C). OVX resulted in thinning of bone trabeculae (red arrows) (D) with the corresponding widening of intertrabecular space (red asterisk) (E). A – control group, B – OVX rats, C – OVX rats after R-HA treatment. Hematoxylin and eosin staining. In figure D, E data presented as the Me (25:75 percentiles). Kruskal-Wallis test was used for comparison. *P < 0.05; * *P < 0.01; * **P < 0.001.

Chondrocytes of the superficial zone were flattened and arranged along with the joint surface. Mid zone comprised chondrocytes in small chondrons surrounded by a metachromatic matrix rich in proteoglycans. The deep zone contained large vacuolated chondrocytes embedded in the intercellular matrix getting calcified toward the subchondral bone. The tidemark, corresponding to the uncalcified and calcified cartilage border, was smooth and aligned parallel to the cartilage surface.

OVX affected both articular cartilage and subchondral bone structure. Estrogen depletion induced by OVX caused regional thinning of cartilage with histological changes suggestive of an altered chondrocyte functioning. Although the mean articular cartilage thickness did not differ significantly as compared to the control group, it demonstrated high heterogeneity and variance. In addition, we observed irregular distribution of chondrocytes and cell dystrophy in the mid and deep

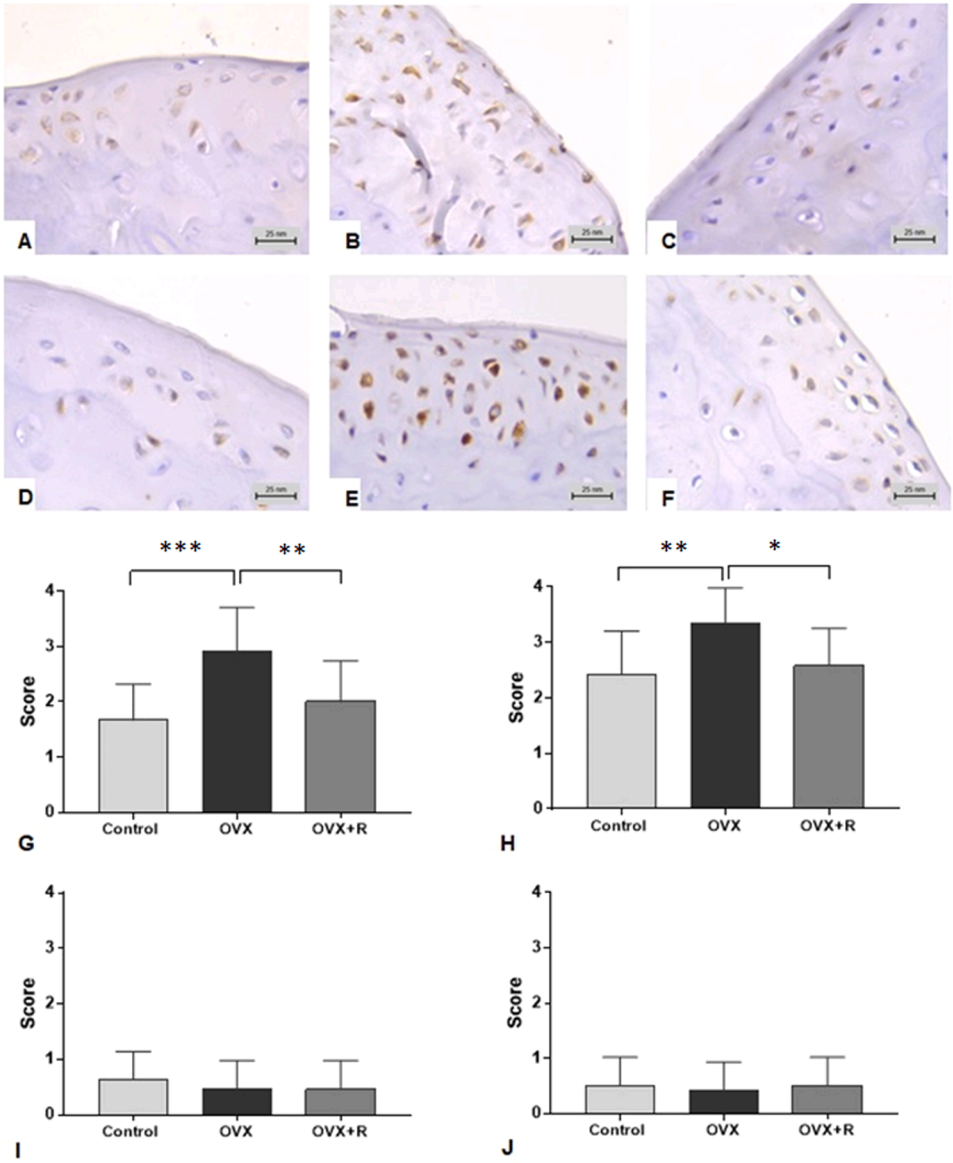

Fig. 4. Altered expression of mTOR and Caspase-3 (Casp-3) in articular cartilage after ovariectomy (OVX) and resveratrol with hyaluronic acid gel (R-HA) treatment. A – C – mTOR expression and D-F – Casp-3 expression in control group (A and D), OVX rats (B and E) and R-HA treated animals (C and F). The increased expression of mTOR and Casp-3 under estrogen depletion was attenuated by R-HA treatment (G, H). I and J demonstrate the low levels of BCL-2 and PTEN expression in chondrocytes of the articular cartilage in all groups. In figure G-J data is presented as the M±SEM. Kruskal-Wallis test was used for comparison. *P < 0.05; * *P < 0.01; * **P < 0.001.

zones with "ghosts" cells (Fig. 2). These features were accompanied by the significant waving of the tidemark and remarkable changes in the subchondral bone plate with its penetration by growing vessels. In addition, the resorption of subchondral trabecular bone was recorded ($P < 0.001$) – TT was significantly lower compared with intact rats (34.1 ± 7.62; 95 % CI 30.6–37.5 vs 50.1 ± 9.56 μm, respectively; $P < 0.001$). This resulted in intertrabecular spaces widening (μm; $P = 0.01$) forming a loose subchondral trabecular bone pattern (Fig. 3).

R-HA treatment attenuated the OVX-induced changes. The thickness of the articular cartilage did not demonstrate significant differences with the OVX and control group. The articular cartilage assessment revealed slight changes in chondrocytes possessing cytoplasm vacuolation in the deep zone and waiving tidemark. TT (42.5 ± 8.58 μm) was higher than in OVX-rats ($P = 0.002$), but lower than in control group ($P = 0.009$) and correspondingly intertrabecular spaces were wider than in OVX ($P = 0.023$) and comparable with the control group ($P = 0.46$) (Fig. 3).

3.3. Biomarkers reflecting the mechanisms of R effects

Although there were no statistically significant differences in the thickness of articular cartilage between groups, OVX rats possessed degenerative changes in chondrocytes, associated with the enhanced expression of Casp-3 ($P = 0.005$) and mTOR ($P < 0.001$) (Fig. 4 G, H). Most chondrocytes of OVX-rats expressed mTOR and its score was significantly higher than that in the control group ($P < 0.001$). Resveratrol decreased mTOR ($P = 0.007$) and Casp-3 ($P = 0.011$) expression in chondrocytes as compared to OVX rats, so the expression of these markers showed no difference from the control group (Fig. 4 G, H). At the same time, BCL-2 and PTEN expression in chondrocytes was low in all groups and was not affected by OVX and R-treatment (Fig. 4 I, J).

Alternatively, in trabecular bone, there was another pattern of biomarkers expression in experimental groups. OVX rats demonstrated reduced expression of BCL-2 ($P = 0.003$), but higher levels of Casp-3 ($P < 0.001$) in osteoblasts covering the trabecular of the subchondral bone of OVX rats. The osteoprotective effect of R-treatment was related to the up-regulation of BCL-2 ($P = 0.018$) and own-regulation of Casp-3 ($P = 0.005$) for restoring the primary levels of antiapoptotic signaling and apoptosis execution (Fig. 5).

4. Discussion

The present study discovered the mechanisms by which R impacts

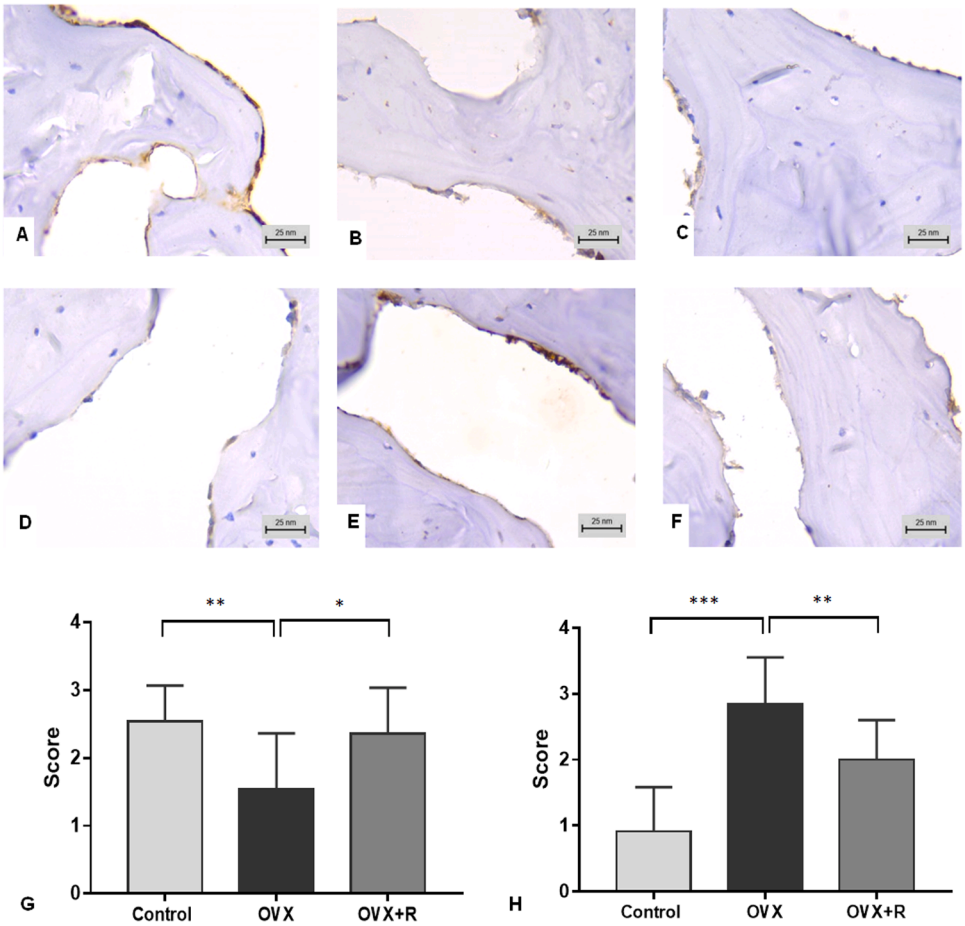

Fig. 5. Resveratrol with hyaluronic acid gel (R-HA) ameliorates apoptotic and signaling pathways in joint tissues of ovariectomized (OVX) rats. OVX was associated with the decline in BCL-2 expression with an alternative elevation for Casp-3 levels. A-C expression of BCL-2 in osteoblasts covering bone trabecules of control (A), OVX (B) and R-HA treated animals (C). G – bar chat demonstrating BCL-2 expression score among observed animals, H – bar chat demonstrating Casp-3 expression score among groups. In figure G-H data presented as the M±SEM. One-way ANOVA was used for comparison. *P < 0.05; * *P < 0.01; * **P < 0.001.

articular tissues under the OVX model in rats. Ovariectomy disrupted the homeostasis of joint tissues, leading to the alteration of articular cartilage and thinning trabecular bone. This effect is due to estrogen depletion, which can activate oxidative stress and various pro-inflammatory pathways, including NF-kB, RANKL, TNF-α, IL-1β, and sclerostin (11,12). Inflammation-mediated mechanisms are crucial for chondrocyte growth and apoptosis regulation as well as for bone tissue resorption control. High levels of IL-1β have been shown to up-regulate Bax and Casp-3 and down-regulate Bcl-2 expression, inducing cell apoptosis [30]. Recent studies have shown that R can attenuate the disruption of various tissue health after a decline of estrogens in both experiments and human studies [31,32]. Our recent study also showed the relationship between Casp-3 and BCL-2 levels in endometrium after OVX and R-treatment [24]. In this study, we tested the hypothesis that intravaginal R-treatment of OVX rats can impact Casp-3 and Bcl-2 expressions in joint tissues.

The study found that intravaginal R treatment had a systemic effect, attenuating weight gain and elevating estradiol levels in OVX rats. The histological examination of joint tissues in OVX rats confirmed the protective effect of R-treatment against degenerative changes in articular cartilage and trabecular bone resorption in estrogen-deficient rats. OVX modeling resulted in dystrophic alteration of chondrocytes and bone trabecular thinning, which was associated with the decline of BCL-2 and an increase in the Casp-3 expression in both chondrocytes and osteoblasts. Casp-3 is a biomarker that reflects cellular apoptosis. Numerous studies have demonstrated the protective effects of R in different models of joint pathology, including experimental osteoarthritis and sodium nitroprusside-induced chondrocyte apoptosis, mediated through ROS and NO generation, followed by the activation of caspases and cytoskeletal remodeling [33–35]. These studies have shown that R has a protective anti-apoptotic effect on chondrocytes [34].

We found that R-HA treatment reduced Casp-3 expression in chondrocytes, supporting the concept of anti-inflammatory and cytoprotective effects of R on cartilage. Similarly, decreased cell apoptosis and down-regulated Casp-3 activity were observed after R-application in nucleus pulposus cells induced by IL-1β. This effect was related to simultaneous down-regulation of gene and protein expression of Bax, increased cleavage of casp-3 and PARP, and up-regulation of anti-apoptotic Bcl-2 expression [30].

In bone tissue, R also reduces apoptosis and promotes osteoblast differentiation, enhancing bone matrix production and mineralization [36]. In this study, elevated expression of BCL-2 was observed under R-action in osteoblasts, indicating that R ameliorated the balance between pro- and antiapoptotic mediators. R-treatment was also shown to be associated with an increase in SIRT1 expression, providing an additional cytoprotective effect on joint tissues [37].

In addition to the cytoprotective effects, R-treatment downregulated mTOR expression in articular cartilage chondrocytes. This effect is crucial for preventing chondrocyte hypertrophy and maintaining cartilage homeostasis. The inhibition of mTOR signaling by R can be mediated through reduced phosphorylation of mTOR and its downstream targets, including p70S6K and 4EBP1 [38]. Additionally, R can activate autophagy, leading to autophagy-mediated mTOR degradation and promoting survival of chondrocytes under OVX conditions [39].

Limitations of the study. This study addressed only early changes in joint tissues after ovariectomy and did not discover long-term effects of OVX and R-treatment. We also did not measure bone mineral density, so there is no data to consider osteopenia and bone-mediated effects on articular cartilage. Another limitation that the phosphorylation of the

mTOR leading to caspase expression was not studied. This study does not cover all the potential mechanisms of apoptosis regulation in joint tissues under ovariectomy and R-action. Further investigations are needed of joint tissues remodeling under R-administration in hypo-estrogenic settings are needed.

5. Conclusion

Intravaginal administration of Resveratrol provided systemic effects and ameliorated joint tissue structure and signaling in OVX rats through stimulation of BCL-2 and downregulation of Casp-3.

Compliance with ethical standards

This study was carried out in strict accordance with the recommendations in the Guide for the Care and Use of Laboratory Animals of the National Institutes of Health and the general ethical principles of animal experiments (Strasbourg, 1985), approved by the First National Congress on Bioethics Ukraine (September 2001). Guide for the Care and Use of Laboratory Animals and approved by the bioethics commission of Bogomolets National Medical University (Protocol number: 4/2021).

Funding

There is none.

CRediT authorship contribution statement

Ganna Zaychenko: Conceptualization, Methodology, Resources, Supervision, Formal analysis. **Igor Belenichev:** Investigation, Funding acquisition, Validation. **Valeriia Hnatiuk:** Investigation, Methodology, Validation. **Andrii Doroshenko**: Formal analysis, Investigation. **Oksana Sinitsyna:** Investigation. **Oksana Sulaieva:** Conceptualization, Methodology, Investigation, Writing – original draft. **Tetyana Falalyeyeva:** Investigation, Writing – review & editing. **Nazarii Kobyliak:** Conceptualization, Supervision, Investigation, Writing – original draft.

Declaration of Competing Interest

The authors declare that the research was conducted in the absence of any commercial or financial relationships that could be construed as a potential conflict of interest.

Data availability

Data will be made available on request to the corresponding author/s.

Acknowledgements

None to declare.

References

[1] C. Griñán-Ferré, A. Bellver-Sanchis, V. Izquierdo, R. Corpas, J. Roig-Soriano, M. Chillón, C. Andres-Lacueva, M. Somogyvári, C. Sőti, C. Sanfeliu, M. Pallàs, The pleiotropic neuroprotective effects of resveratrol in cognitive decline and Alzheimer's disease pathology: from antioxidant to epigenetic therapy, Ageing Res. Rev. 67 (2021), 101271, https://doi.org/10.1016/j.arr.2021.101271.

[2] M.A. McNeil, S.B. Merriam, Menopause, Ann. Intern. Med. 174 (2021) ITC97–ITC112, https://doi.org/10.7326/AITC202107200.

[3] S.-H. Ko, H.-S. Kim, Menopause-associated lipid metabolic disorders and foods beneficial for postmenopausal women, Nutrients 12 (2020), https://doi.org/10.3390/nu12010202.

[4] C. Sousa-Lages, L. Deus-Lages, G. Sousa, A. Moura-Leal, J. Conde, D. Costa-Silva, M. Barros-Oliveira, C. Borges, C. Escórcio-Dourado, F. Sampaio, L. Cunha-Nunes, B. Silva, Effect of a gel containing pilocarpine on vaginal atrophy in castrated rats, Clinics 71 (2016) 291–294, https://doi.org/10.6061/clinics/2016(05)09.

[5] M. Tsoumani, P.E. Nikolaou, A. Argyropoulou, I. Tseti, S. Mitakou, I. Andreadou, Novel evidence-based combination of plant extracts with multitarget mechanisms of action for the elimination of hot flashes during menopause, Mollecules 27 (2022) 1221, https://doi.org/10.3390/MOLECULES27041221.

[6] A.H.E.M. Maas, G. Rosano, R. Cifkova, A. Chieffo, D. van Dijken, H. Hamoda, V. Kunadian, E. Laan, I. Lambrinoudaki, K. Maclaran, N. Panay, J.C. Stevenson, M. van Trotsenburg, P. Collins, Cardiovascular health after menopause transition, pregnancy disorders, and other gynaecologic conditions: a consensus document from European cardiologists, gynaecologists, and endocrinologists, Eur. Heart J. 42 (2021) 967–984, https://doi.org/10.1093/eurheartj/ehaa1044.

[7] V.M. Miller, J.M. Kling, J.A. Files, M.J. Joyner, E. Kapoor, A.M. Moyer, W.A. Rocca, S.S. Faubion, What's in a name: are menopausal "hot flashes" a symptom of menopause or a manifestation of neurovascular dysregulation? Menopause 25 (2018) 700–703, https://doi.org/10.1097/GME.0000000000001065.

[8] R. Marongiu, Accelerated ovarian failure as a unique model to study peri-menopause influence on Alzheimer's disease, Front. Aging Neurosci. 11 (2019), https://doi.org/10.3389/fnagi.2019.00242.

[9] S. Jett, N. Malviya, E. Schelbaum, G. Jang, E. Jahan, K. Clancy, H. Hristov, S. Pahlajani, K. Niotis, S. Loeb-Zeitlin, Y. Havryliuk, R. Isaacson, R.D. Brinton, L. Mosconi, Endogenous and exogenous estrogen exposures: how women's reproductive health can drive brain aging and inform Alzheimer's prevention, Front. Aging Neurosci. 14 (2022), https://doi.org/10.3389/fnagi.2022.831807.

[10] F.M. OlaOlorun, W. Shen, Menopause, in: in: Oxford Research Encyclopedia of Global Public Health, Oxford University Press, 2020, https://doi.org/10.1093/acrefore/9780190632366.013.176.

[11] S. Khosla, D.G. Monroe, Regulation of bone metabolism by sex steroids, Cold Spring Harb. Perspect. Med. 8 (2018) a031211, https://doi.org/10.1101/CSHPERSPECT.A031211.

[12] M.-L. Pérez-Lozano, A. Cesaro, M. Mazor, E. Esteve, S. Berteina-Raboin, T.M. Best, E. Lespessailles, H. Toumi, Emerging natural-product-based treatments for the management of osteoarthritis, Antioxidants 10 (2021) 265, https://doi.org/10.3390/antiox10020265.

[13] M. Glisic, N. Kastrati, J. Musa, J. Milic, E. Asllanaj, E. Portilla Fernandez, J. Nano, C. Ochoa Rosales, M. Amiri, B. Kraja, A. Bano, W.M. Bramer, A.J.M. Roks, A.H. J. Danser, O.H. Franco, T. Muka, Phytoestrogen supplementation and body composition in postmenopausal women: a systematic review and meta-analysis of randomized controlled trials, Maturitas 115 (2018) 74–83, https://doi.org/10.1016/j.maturitas.2018.06.012.

[14] R.J. Qasem, The estrogenic activity of resveratrol: a comprehensive review of in vitro and in vivo evidence and the potential for endocrine disruption, Crit. Rev. Toxicol. 50 (2020) 439–462, https://doi.org/10.1080/10408444.2020.1762538.

[15] T. Meng, D. Xiao, A. Muhammed, J. Deng, L. Chen, J. He, Anti-Inflammatory action and mechanisms of resveratrol, Molecules 26 (2021) 229, https://doi.org/10.3390/MOLECULES26010229.

[16] A. Kaur, R. Tiwari, G. Tiwari, V. Ramachandran, Resveratrol: a vital therapeutic agent with multiple health benefits, Drug Res. 72 (2022) 5–17, https://doi.org/10.1055/a-1555-2919.

[17] I. Gasparova, P. Kubatka, R. Opatrilova, M. Caprnda, S. Filipova, L. Rodrigo, L. Malan, I. Mozos, M. Rabajdova, V. Nosal, N. Kobyliak, V. Valentova, D. Petrovic, M. Adamek, P. Kruzliak, Perspectives and challenges of antioxidant therapy for atrial fibrillation, Naunyn Schmiedeberg's Arch. Pharmacol. 390 (2017) 1–14, https://doi.org/10.1007/s00210-016-1320-9.

[18] N. Belemets, N. Kobyliak, O. Virchenko, T. Falalyeyeva, T. Olena, P. Bodnar, O. Savchuk, T. Galenova, M. Caprnda, L. Rodrigo, L. Skladany, D. Delev, R. Opatrilova, P. Kruzliak, T. Beregova, L. Ostapchenko, Effects of polyphenol compounds melanin on NAFLD/NASH prevention, Biomed. Pharmacother. 88 (2017), https://doi.org/10.1016/j.biopha.2017.01.028.

[19] H.J. Kim, H.J. Braun, J.L. Dragoo, The effect of resveratrol on normal and osteoarthritic chondrocyte metabolism, Bone Jt. Res. 3 (2014) 51–59, https://doi.org/10.1302/2046-3758.33.2000226.

[20] M. Zhao, S.-Y. Ko, I.R. Garrett, G.R. Mundy, G.E. Gutierrez, J.R. Edwards, The polyphenol resveratrol promotes skeletal growth in mice through a sirtuin 1-bone morphogenic protein 2 longevity axis, Br. J. Pharmacol. 175 (2018) 4183–4192, https://doi.org/10.1111/bph.14477.

[21] T. Yu, Z. Wang, X. You, H. Zhou, W. He, B. Li, J. Xia, H. Zhu, Y. Zhao, G. Yu, Y. Xiong, Y. Yang, Resveratrol promotes osteogenesis and alleviates osteoporosis by inhibiting p53, Aging 12 (2020) 10359–10369, https://doi.org/10.18632/aging.103262.

[22] G. Bhattarai, S.B. Poudel, S.-H. Kook, J.-C. Lee, Resveratrol prevents alveolar bone loss in an experimental rat model of periodontitis, Acta Biomater. 29 (2016) 398–408, https://doi.org/10.1016/j.actbio.2015.10.031.

[23] J. Feng, S. Liu, S. Ma, J. Zhao, W. Zhang, W. Qi, P. Cao, Z. Wang, W. Lei, Protective effects of resveratrol on postmenopausal osteoporosis: regulation of SIRT1-NF-kappa B signaling pathway, Acta Biochim. Et. Biophys. Sin. 46 (2014) 1024–1033, https://doi.org/10.1093/abbs/gmu103.

[24] G. Zaychenko, O. Stryga, O. Sinitsyna, A. Doroshenko, O. Sulaieva, T. Falalyeyeva, N. Kobyliak, Resveratrol effects on the reproductive system in ovariectomized rats: deciphering possible mechanisms, Molecules 27 (2022) 4916, https://doi.org/10.3390/MOLECULES27154916.

[25] M. Holz, Crosstalk between mTOR and estrogen signaling, FASEB J. 34 (2020) 1, https://doi.org/10.1096/fasebj.2020.34.s1.00221.

[26] J. Liu, X. Lv, Resveratrol relive osteoarthritis through reducing inflammatory reactions, Int. J. Clin. Exp. Med., 12 (n.d.) 5177–5183.

[27] M.A. Khayum, E.F.J. de Vries, A.W.J.M. Glaudemans, R.A.J.O. Dierckx, J. Doorduin, In vivo imaging of brain estrogen receptors in rats: a 16α- 18 F-Fluoro-

17β-Estradiol PET study, J. Nucl. Med. 55 (2014) 481–487, https://doi.org/10.2967/jnumed.113.128751.

[28] N. Yousefzadeh, K. Kashfi, S. Jeddi, A. Ghasemi, Ovariectomized rat model of osteoporosis: a practical guide, Excli J. 19 (2020) 89–107, https://doi.org/10.17179/excli2019-1990.

[29] O. Korotkyi, K. Dvorshchenko, T. Falalyeyeva, O. Sulaieva, N. Kobyliak, L. Abenavoli, S. Fagoonee, R. Pellicano, L. Ostapchenko, Combined effects of probiotic and chondroprotector during osteoarthritis in rats, Panminerva Med. 62 (2020), https://doi.org/10.23736/S0031-0808.20.03841-0.

[30] Y. Jiang, Z. Xie, J. Yu, L. Fu, Resveratrol inhibits IL-1β-mediated nucleus pulposus cell apoptosis through regulating the PI3K/Akt pathway, Biosci. Rep. 39 (2019), BSR20190043, https://doi.org/10.1042/BSR20190043.

[31] J.J. Thaung Zaw, P.R.C. Howe, R.H.X. Wong, Long-term resveratrol supplementation improves pain perception, menopausal symptoms, and overall well-being in postmenopausal women: findings from a 24-month randomized, controlled, crossover trial, Menopause 28 (2021) 40–49, https://doi.org/10.1097/GME.0000000000001643.

[32] V. Fabricio, J.C. Oishi, B.G. Biffe, L.D.G. Ruffoni, K.A. da Silva, K.O. Nonaka, G. J. Rodrigues, Resveratrol treatment normalizes the endothelial function and blood pressure in ovariectomized rats, Arq. Bras. De. Cardiol. (2017), https://doi.org/10.5935/abc.20170012.

[33] K.P.L. Bhat, J.W. Kosmeder, J.M. Pezzuto, Biological effects of resveratrol, Antioxid. Redox Signal. 3 (2001) 1041–1064, https://doi.org/10.1089/152308601317203567.

[34] Q. Liang, X.P. Wang, T.S. Chen, Resveratrol protects rabbit articular chondrocyte against sodium nitroprusside-induced apoptosis via scavenging ROS, Apoptosis Int. J. Program. Cell Death 19 (2014) 1354–1363, https://doi.org/10.1007/S10495-014-1012-1.

[35] S. Yang, M. Sun, X. Zhang, Protective effect of resveratrol on knee osteoarthritis and its molecular mechanisms: a recent review in preclinical and clinical trials, Front. Pharmacol. 13 (2022), 921003, https://doi.org/10.3389/FPHAR.2022.921003.

[36] N. He, X. Zhu, W. He, S. Zhao, W. Zhao, C. Zhu, Resveratrol inhibits the hydrogen dioxide-induced apoptosis via Sirt 1 activation in osteoblast cells, Biosci. Biotechnol. Biochem. 79 (2015) 1779–1786, https://doi.org/10.1080/09168451.2015.1062712.

[37] Y.H. Noh, D.H. Kim, S.A. Lee, X.F. Yin, J. Park, M.Y. Lee, W.B. Lee, S.H. Lee, J. K. Kim, S.S. Kim, Y. Jeong, S.C. Myung, T.J. Kim, I.J. Kang, The natural substance MS-10 improves and prevents menopausal symptoms, including Colpoxerosis, in clinical research, J. Med. Food 19 (2016) 228–237, https://doi.org/10.1089/JMF.2015.3547.

[38] M. Liu, S.A. Wilk, A. Wang, L. Zhou, R.H. Wang, W. Ogawa, C. Deng, L.Q. Dong, F. Liu, Resveratrol inhibits mTOR signaling by promoting the interaction between mTOR and DEPTOR, J. Biol. Chem. 285 (2010) 36387–36394, https://doi.org/10.1074/JBC.M110.169284.

[39] Z. Wu, X. Zhang, Z. Li, Z. Wen, Y. Lin, Activation of autophagy contributes to the protective effects of lycopene against oxidative stress-induced apoptosis in rat chondrocytes, Phytother. Res. PTR 35 (2021) 4032–4045, https://doi.org/10.1002/PTR.7127.

[40] L.C. Flores-García, J.L. Ventura-Gallegos, S.L. Romero-Córdoba, A.J. Hernández-Juárez, M.A. Naranjo-Meneses, E. García-García, J.P. Méndez, A.J. Cabrera-Quintero, A. Ramírez-Ruíz, S. Pedraza-Sánchez, N. Meraz-Cruz, F. Vadillo-Ortega, A. Zentella-Dehesa, Sera from women with different metabolic and menopause states differentially regulate cell viability and Akt activation in a breast cancer in-vitro model, PLoS One 17 (2022), e0266073, https://doi.org/10.1371/journal.pone.0266073.